DEPARTMENT OF MEDICAL IMAGING
UNIVERSITY OF TORONTO

Sunnybrook
HEALTH SCIENCES CENTRE

VERTEBROPLASTY – BEST PRACTICE

ELIZABETH DAVID

DEPARTMENT OF MEDICAL IMAGING, INTERVENTIONAL RADIOLOGY

SUNNYBROOK HEALTH CENTRE

UNIVERSITY OF TORONTO, CANADA

INTRODUCTION

To understand the evolving role of vertebroplasty in the management of osteoporotic fractures

To briefly understand the techniques and explain the difference between kyphoplasty and vertebroplasty

To briefly discuss the results of several trials, cochrane analysis and our own ministry of health analysis

Briefly describe the evolving role of vertebroplasty and osteoplasty in the management of pathological fractures and insufficiency fractures sustained during cancer treatments

VERTEBROPLASTY IN OSTEOPOROSIS

Vertebral compression fractures are very common in osteoporosis. Presents with pain and impaired mobility. Treatment depends on patient's symptoms, location of fracture, type of fracture and age of fracture.

Conservative therapy (braces, medical therapy)

Invasive options: Surgical, percutaneous options such as vertebroplasty and kyphoplasty

Technique was first reported in 1987 (first case was in a haemangioma)

Kyphoplasty has not been shown to be superior to vertebroplasty with respect to fracture stabilization and pain control. It is 4x more expensive (higher material costs and billing costs).

No clear evidence that kyphoplasty restores height; sole advantage appears to be in control of cement injection.

VERTEBROPLASTY

Meta analysis done by Health Quality Ontario demonstrated that in a subset of patients with painful VCFs refractory to analgesia or requiring increasing amounts of analgesia, vertebroplasty is superior to conservative treatment with respect to quality of life and reducing pain/disability and ongoing vertebral collapse

Predictors of success:

- Acute to subacute fracture (less than 6-12 weeks) with focal mechanical pain (exacerbated with motion, coughing); no significant radicular component. Bone edema on MR, air within fracture cleft or visible fracture cleft on CT.

Predictors of poor outcome

- Chronic fractures, not clearly mechanical pain.

  Radicular component is dominant.

  No bone edema or visible fracture cleft on CT.

VERTEBROPLASTY

NEJM published an Australian trial in 2009 which raised questions about role of vertebroplasty.

131 patients who had 1-3 painful osteoporotic fractures randomized to vertebroplasty vs sham (periosteal infiltration with marcaine). Primary outcomes were scores on the modified Roland Morris Disability questionnaire (0-23) with higher scores indicating greater disability. Patients were allowed to cross over into other group after 1 month (to increase enrollment).

68 vertebroplasties and 63 sham procedures. Decreased level of pain required to 3/10 to enroll more patients. Excluded inpatients and no acute fractures (under 6 weeks) treated

Both groups had immediate improvement in disability and pain scores after the intervention.

There was a trend toward higher rate of clinically meaningful improvement in pain (30% decrease from baseline) in vertebroplasty group. Also at 3 months there was a higher cross over from sham to vertebroplasty group than other way around (43% vs 12%).

Fractures had to be less than 1 year old. Excluded fractures were suspected neoplasm, retropulsed fragments, hospitalized patients

PROBLEMS WITH THE STUDY

Trend to improved pain control in vertebroplasty arm; was trial underpowered (i.e. P too small)?

Pain of greater than 3; used to increase enrollment; were they selecting people with mild pain who likely did not require treatment

Exclusion of pathological fractures and inpatients. Potential exclusion of subset of patients who would benefit the most from this intervention

Use of long acting bupivacaine; which we use for nerve blocks with very good success.

VAPOUR TRIAL

Multicenter trial, 120 patients (61 vert and 59 sham) with 1-2 acute osteoporotic fractures under 6 weeks, pain greater than 7/10; only trial to include hospitalized patients

Randomized to procedure or sham. Sham only involved subcutaneous lidocaine injection (no periosteal infiltration).

Patients treated with vertebroplasty all reached endpoint (pain score under 4/10) faster than conservative arm. Mean hospital stay reduced by 5.5 days.

Reduced analgesia use in vertebroplasty arm.

Treated fractures also maintained height compared to conservative therapy where ongoing collapse occurred.

Used vertebral fill technique (larger amounts of cement injected into vertebral body). Larger amounts (8 cc) can be injected when fracture clefts are unstable and bone is plastic or mobile.

VAPOUR TRIAL

Two adverse events in vertebroplasty arm (respiratory arrest post sedation and humeral fracture in positioning patient on table)

In conservative arm, 2 patients went on to spinal cord compression from continued collapse and retropulsed fragments.

Best results obtained at the thoracolumbar junction (T11-L2) likely due to hypermobility of this segment.

Conclusion of trial was that VP was superior to conservative management in fracture under 6 weeks, especially in thoracolumbar junction. T11-L2

VERTOS 4

Recruited outpatients from xrays. Pain level for inclusion >5/10 and duration under 9 weeks. No inpatients. Mean time of vertebroplasty was at 12 weeks.

Primary outcome was equivalent in both groups re pain reduction. There was height preservation in the treatment group.

Vertebroplasty did not increase risk for fractures at other levels.

WHAT DO THESE TRIALS TELL US

Cochrane review decided that there is no evidence for use of vertebroplasty in the setting of osteoporotic fractures based on metaanalysis but there were issues with what data they included.

We know that the story is more complex

Vapour was the only trial that allowed treatment of hyperacute fractures in patients with severe pain >7/10 even on opiods and many were hospitalized.

Intuitively this appears to be the population that would receive the greatest benefit from this procedure.

In addition vertebral augmentation results in early mobilization, stops ongoing collapse, kyphosis and preserves spinal alignment.

PATIENT SELECTION

In the osteoporotic group, the population that most benefits from this intervention is older, frailer, does not tolerate opioids or immobilization and has clear localized mechanical pain related to the fracture level; usually greater than 7/10 with opioids.

Larger cement volumes usually allow for improved stabilization.

KYPHOPLASTY VS VERTEBROPLASTY

No significant height restoration in kyphoplasty. There is more control in cement injection.

A mechanical cavity is created within which cement in injected. We can do the same with RFA and creation of a thermal cavity.

WHAT ABOUT PATHOLOGICAL FRACTURES?

There is clear evidence that stabilization of pathological fractures in the cancer patient has benefits that outweigh risks.

Patients who have had radiation, ongoing chemotherapy or steroids benefit from stabilization especially where there is impaired callous formation post SBRT.

TECHNIQUE

13, 11 or 10 gauge

Can biopsy at same time

Unipedicular versus Bipedicular

RFA assisted (thermal cavity) versus kypho (mechanical cavity) – goal is to obtain good vertebral fill

Type of cement used (thickness, antibiotic infused)

Evolving roles of PDT and RFA especially in malignancy

COMPLICATIONS: RATE LESS THAN 1%

Commonly related to sedation and is respiratory (patient is prone on the table)

Cement leaks are usually asymptomatic. Cement leaks into epidural space if low volume rarely have any clinical effects; larger volumes can impinge on nerve roots or cord (very rare)

Cement leaks into discs (potential issue with adjacent level fractures although vertos 4 suggests this is not true)

Cement leaks anteriorly not clinically relevant

Cement leaks into veins can result in small volume subsegmental pulmonary emboli. Rarely symptomatic unless patient has underlying lung disease.

Cement leaks decreased with RFA.

54 YEAR OLD WOMAN, OSTEOPOROTIC

75 YEAR OLD WOMAN WITH MYLEODYSPLASTIC SYNDROME; PAIN 9/10; IMMOBILE

CASES: 65 YEAR OLD PAIN FOR 2 MONTHS

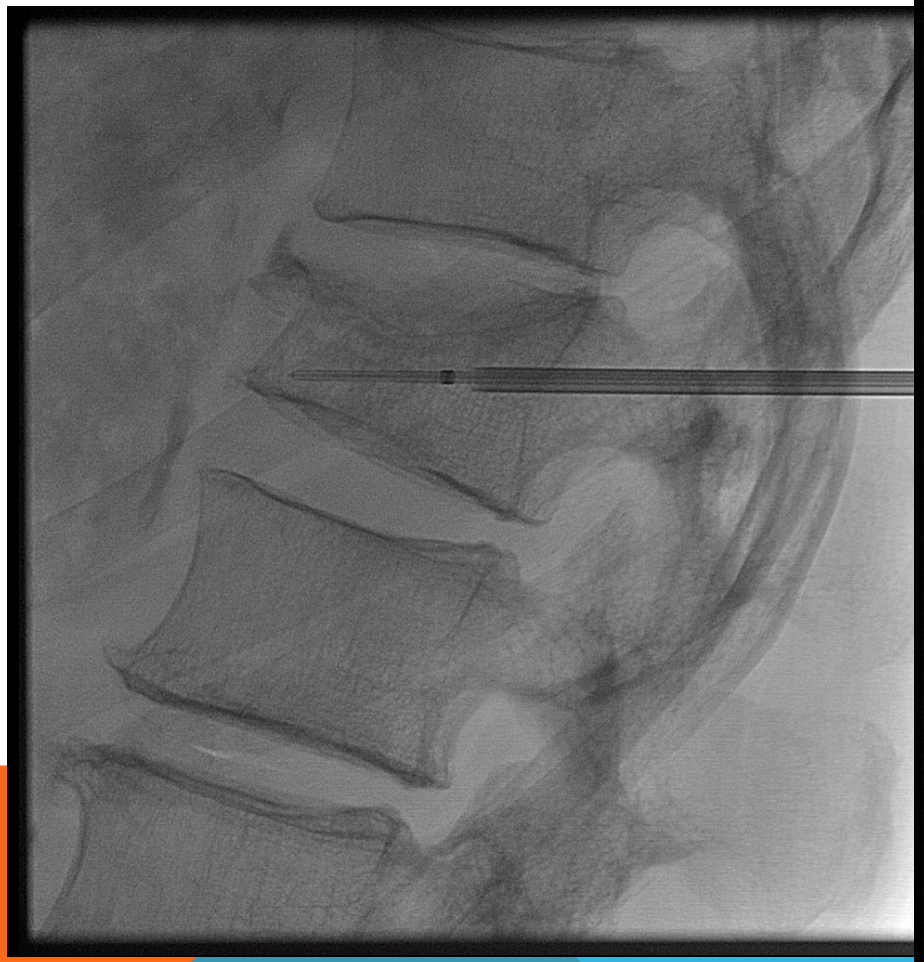

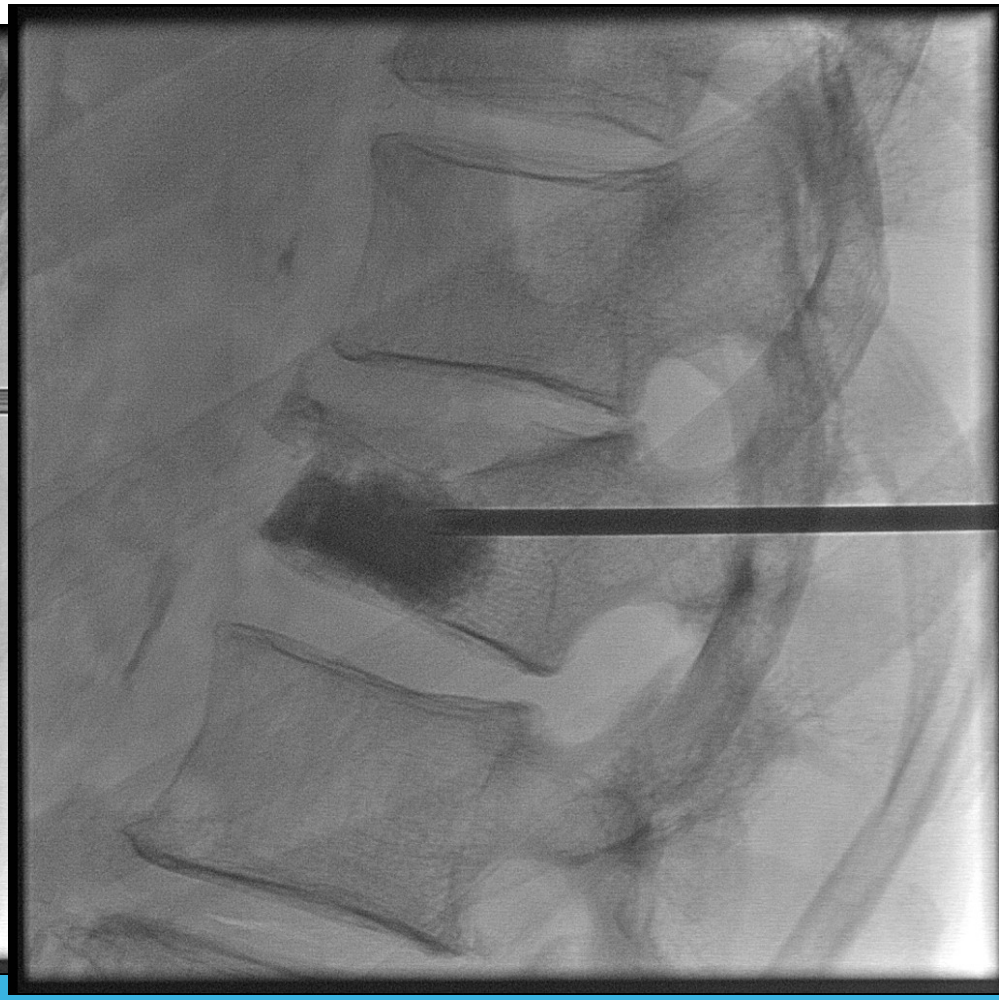

RESULTS

70 YR OLD WITH LUNG CA 3 WEEKS PAIN POST SBRT

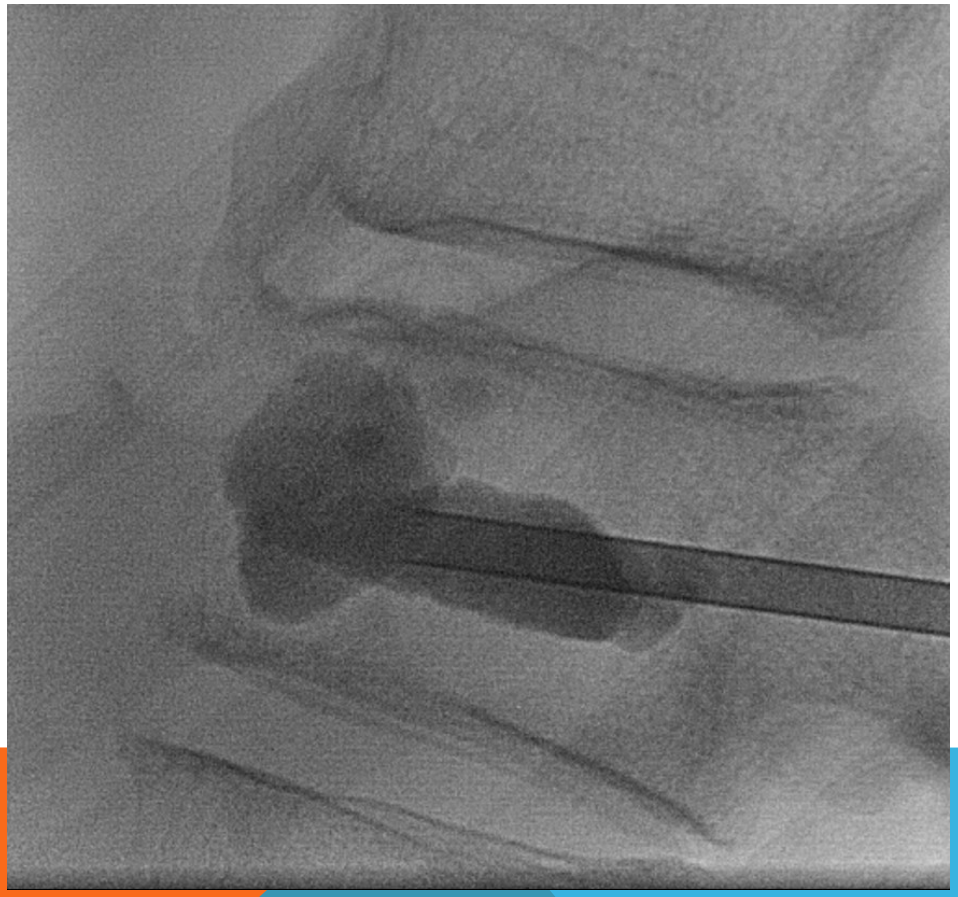

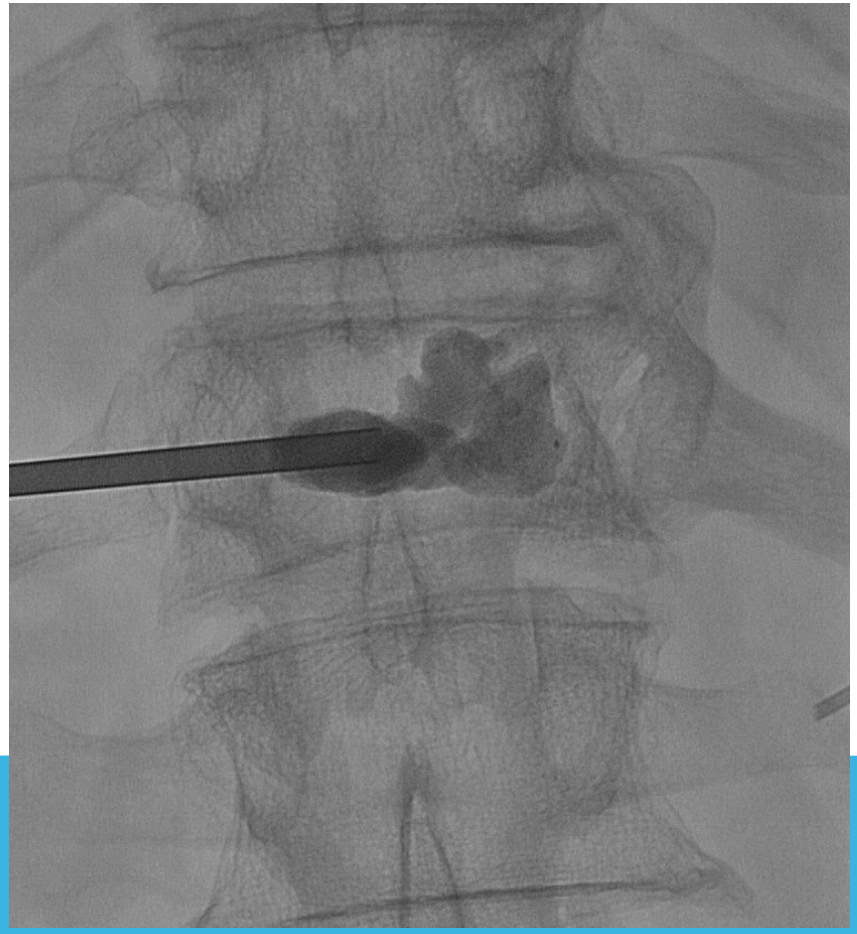

POST

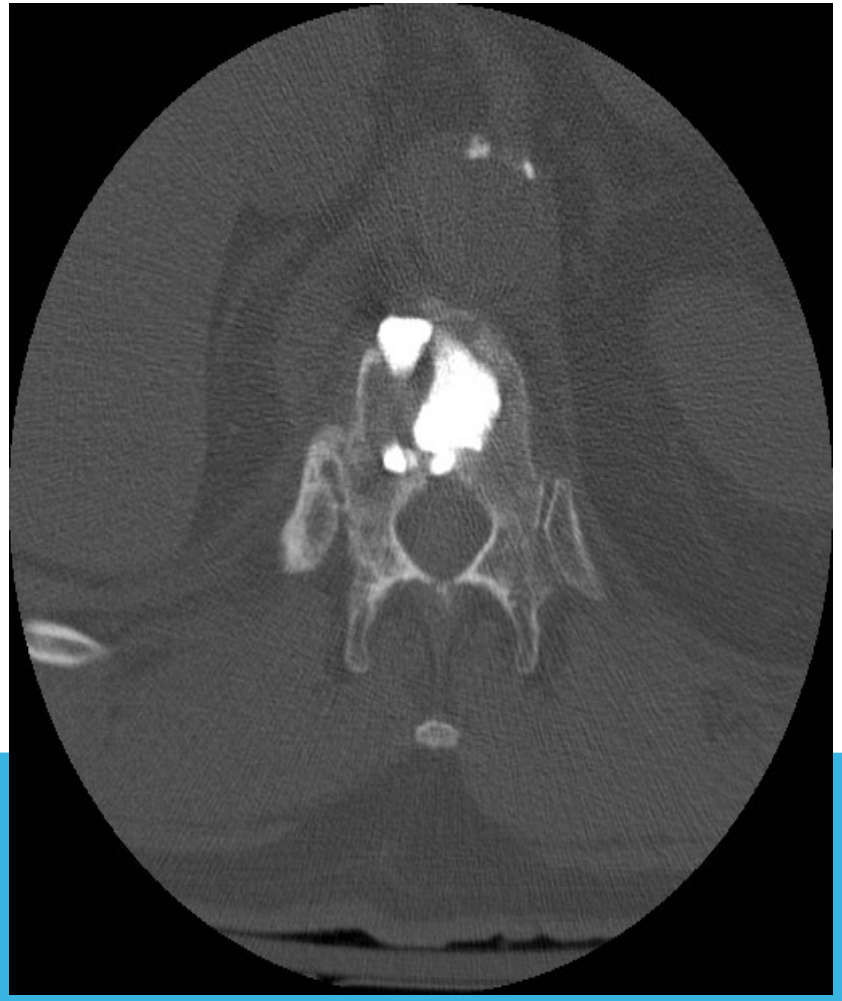

88 YEAR OLD MALE WITH MET. PROSTATE CANCER

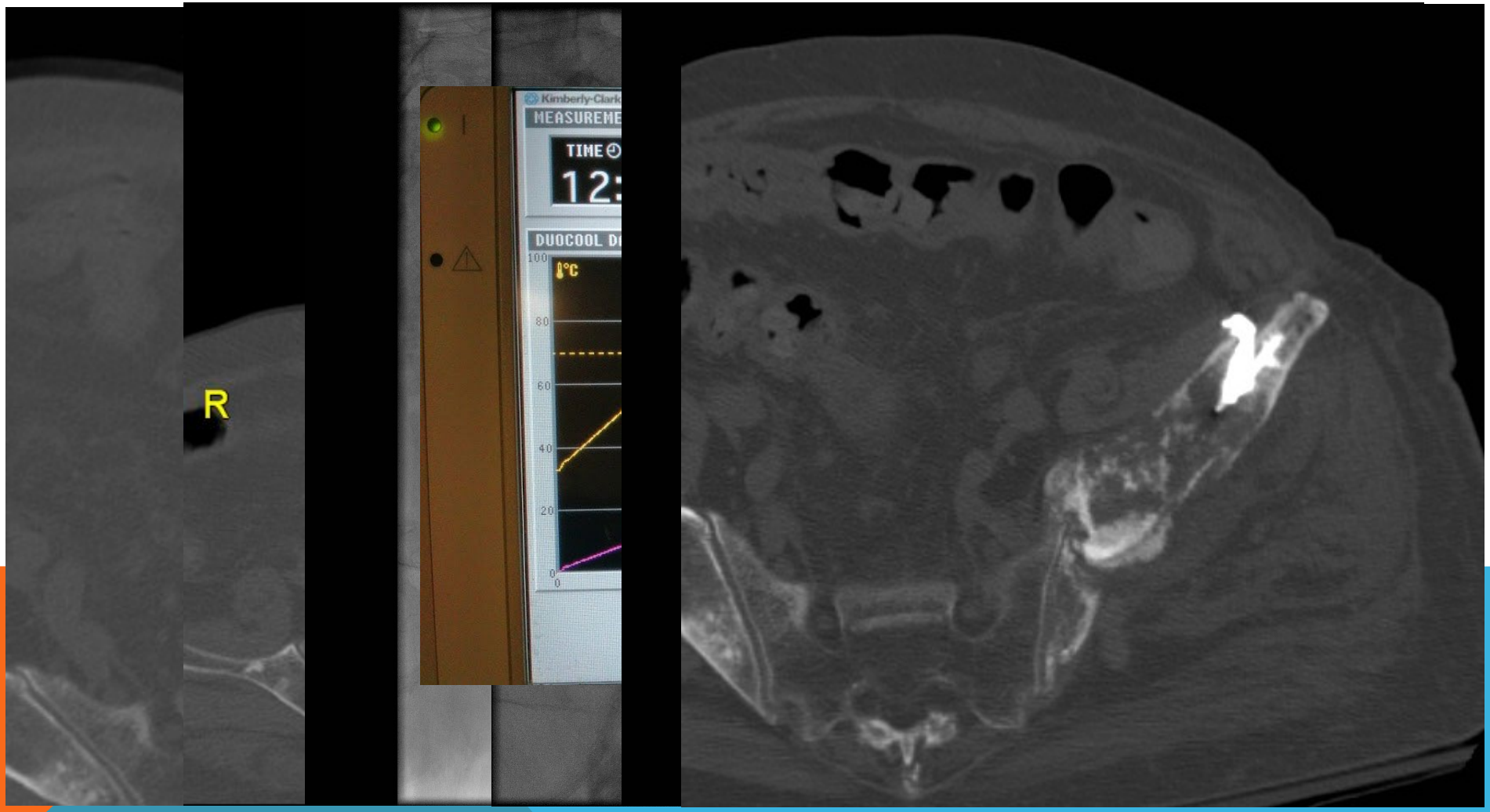

SACROPLASTY – BENIGN AND INSUFFICIENCY FRACTURES

WHEN TO CONSIDER VERTEBROPLASTY/OSTEOPLASTY

Older patient

Non ambulatory

Requiring larger amounts of narcotics or not coping with narcotics and conservative management

Pain unremitting greater than 2 weeks

Burst fracture (no cord impingement)

Greater than 50% height loss, ongoing rapid collapse

Neurologically intact, clear mechanical pain

CONCLUSION

Vertebroplasty is superior to placebo or conservative therapy in the treatment of acute osteoporotic fractures of less than 6 weeks duration

It has a role in preventing ongoing morbidity and narcotic dependence and preserving spinal alignment

It has a high safety profile in experienced hands.

It reduces hospital inpatient requirement and is economically helpful in decreasing costs as per HQO.

WHY THE CONTROVERSY

Constant tension between patient need/service providers and cost containment

Need to find balance between overuse and underuse

There is value in this procedure but it needs to be used sparingly in appropriate settings

We need to reconsider use of more costly interventions such as kyphoplasty in the absence of clear benefits. We do know however that there is a decreased rate of cement leaks for this intervention so there is a clear role when combined with open surgical decompression interventions.

Remember the only alternative to VCF is conservative treatment which is pain management (often opiod use) and immobilization. Both of these carry their own risk profile.

THANK YOU

REFERENCES

1. Peter L. Munk, Faisal Rashid, Manraj K. Heran, Michael Papirny, David M. Liu, David Malfair, Maziar Badii and Paul W. Clarkson. Combined cementoplasty and radiofrequency ablation in the treatment of painful neoplastic lesions of bone. J Vasc Interv Radiol. 2009 Jul;20(7):903-11
2. Ralf Thorsten Hoffmann, Tobias F. Jakobs, Christoph Trumm, Christof Weber, Thomas K. Helmberger, and Maximilian F. Reiser. Radiofrequency Ablation in Combination with Osteoplasty in the Treatment of Painful Metastatic Bone Disease. J Vasc Interv Radiol 2008; 19:419 – 425
3. M Gofeld, AJM Yee, CM Whyne, MK Akens, P Pezeshki, J Woo, New Palliative Intervention for PainfulMetastatic Bone Disease - The OsteoCool™ System. European Cells and Materials Vol. 23. Suppl. 3, 2012 (page 11)

Percutaneous vertebroplasty for osteoporotic vertebral compression fracture. Cochrane Database Syst Rev 2018;ovel Bone Tumor RF Ablation System – Physics and Animal Data . GRIBOI, 2011, pp. 46

REFERENCES

Clark W ,

Bird P ,

Gonski P , *et al*

. Safety and efficacy of vertebroplasty for acute painful osteoporotic fractures (VAPOUR): a multicentre, randomised, double-blind, placebo-controlled trial. Lancet 2016;388

Firanescu CE ,

de Vries J ,

Lodder P , *et al*

. Vertebroplasty versus sham procedure for painful acute osteoporotic vertebral compression fractures (VERTOS IV): randomised sham controlled clinical trial. BMJ 2018:k1551

Klazen CA ,

Lohle PN ,

de Vries J , *et al*

. Vertebroplasty versus conservative treatment in acute osteoporotic vertebral compression fractures (Vertos II): an open-label randomised trial. Lancet2010;376:1085–92

THANK YOU

Questions?